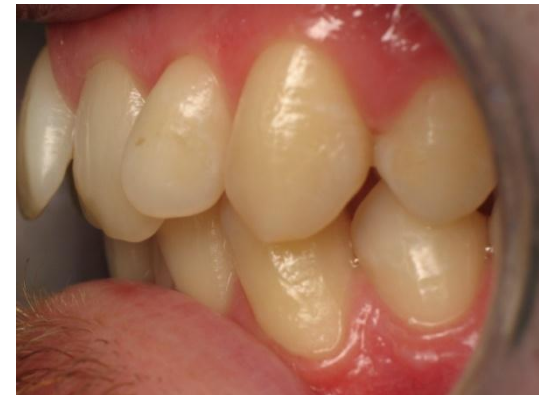
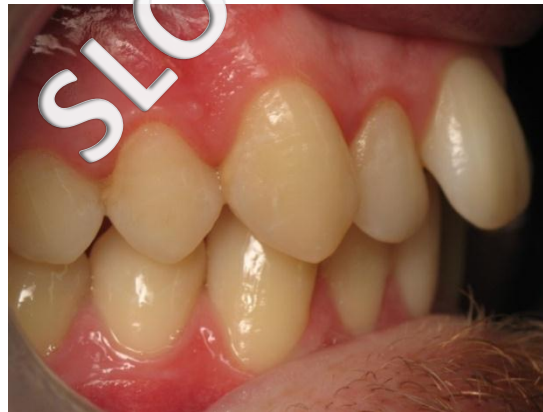
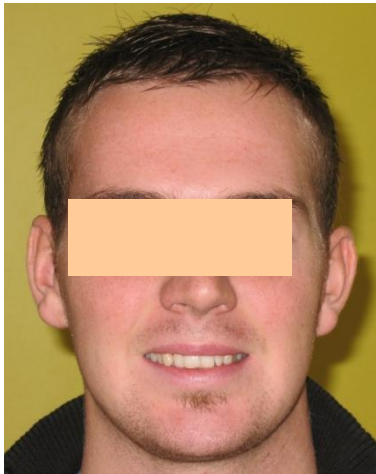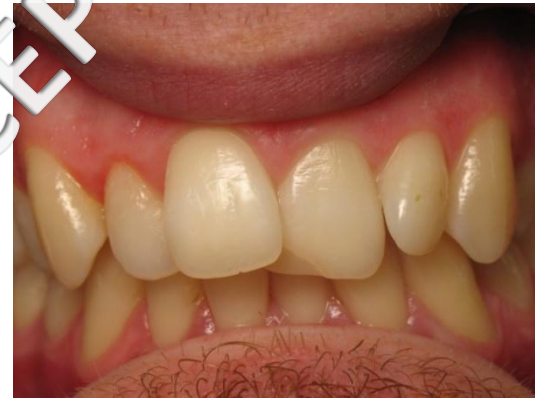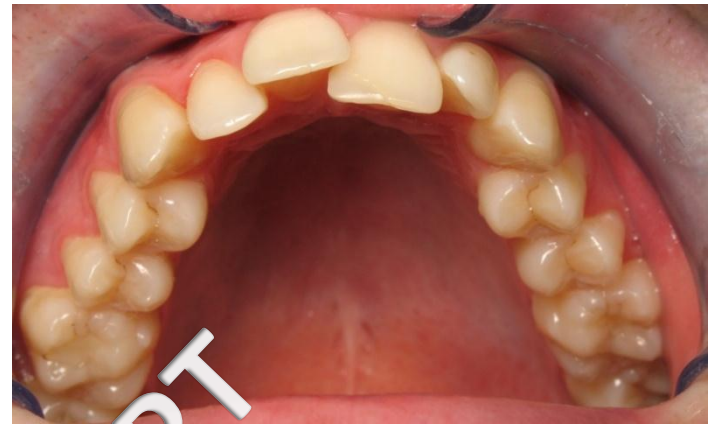## CASE

- **PRETREATMENT**

Male, 21 years old . His primary complaint was that her front teeth were crowded  
Only five months of treatment!



- **TREATMENT OBJECTIVES**

- Simple alignment with lingual 2 D low cost

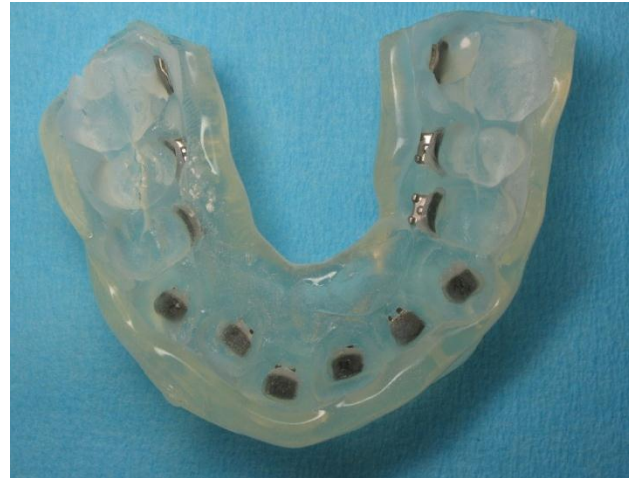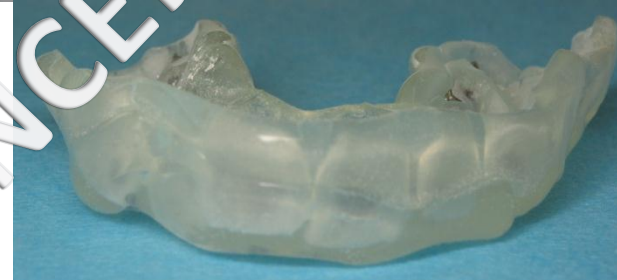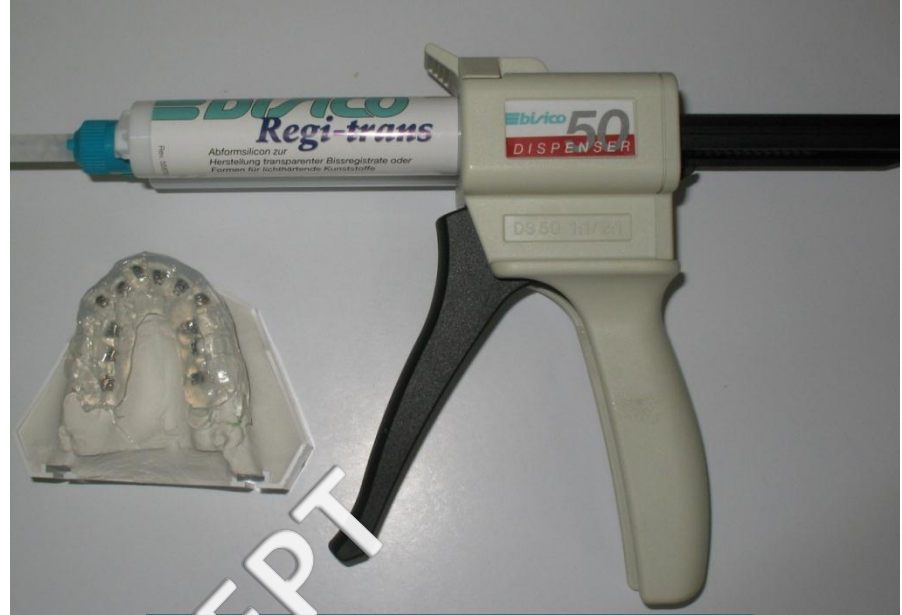- Indirect bonding tool With easy silicon method

with

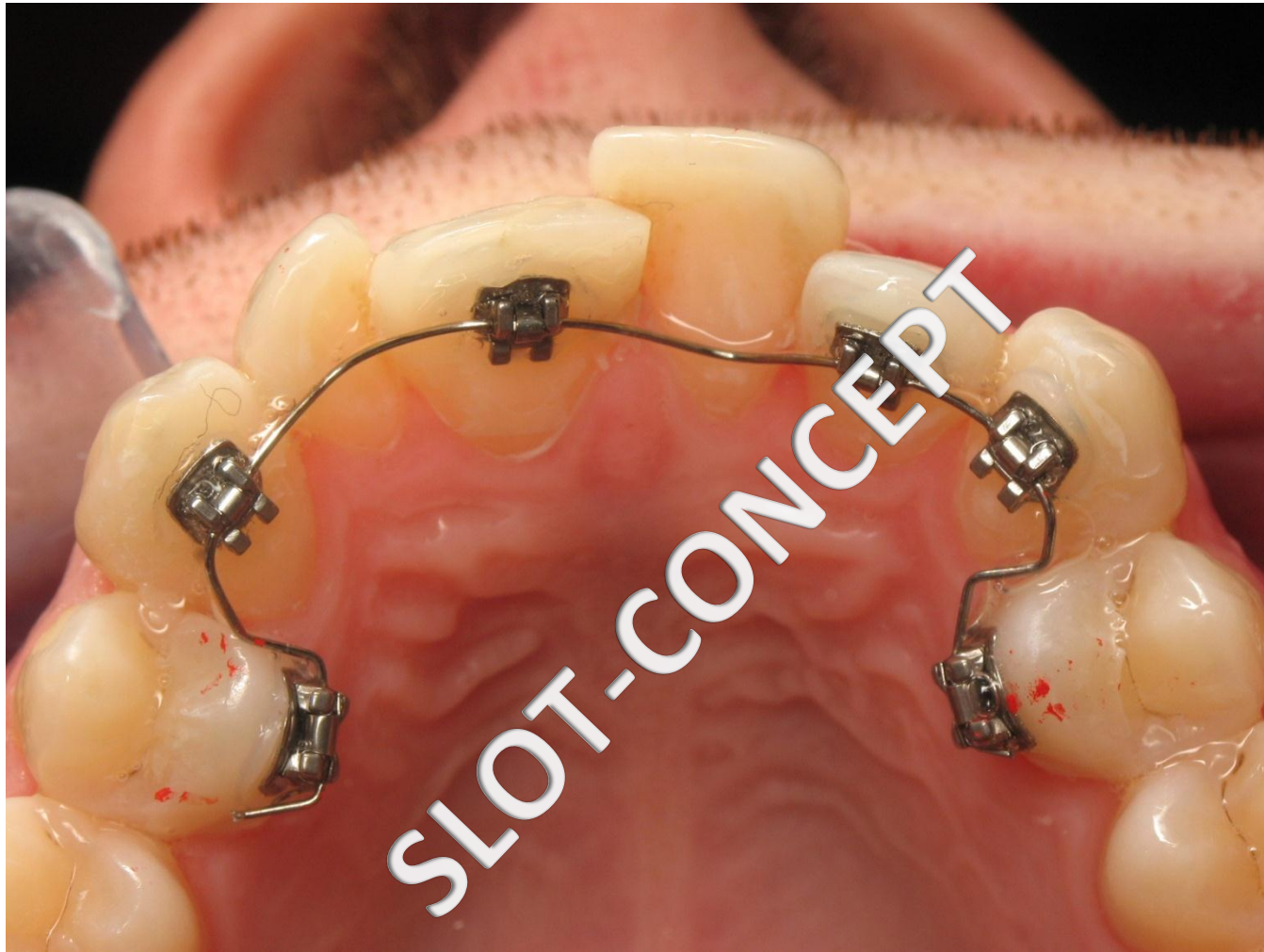- regi-trans de bisico
- Memosyl !

Method of indirect easier without dental laboratory without target or any 3 D information

Obligation to use only round wire



# 1<sup>st</sup> APPOINTMENT

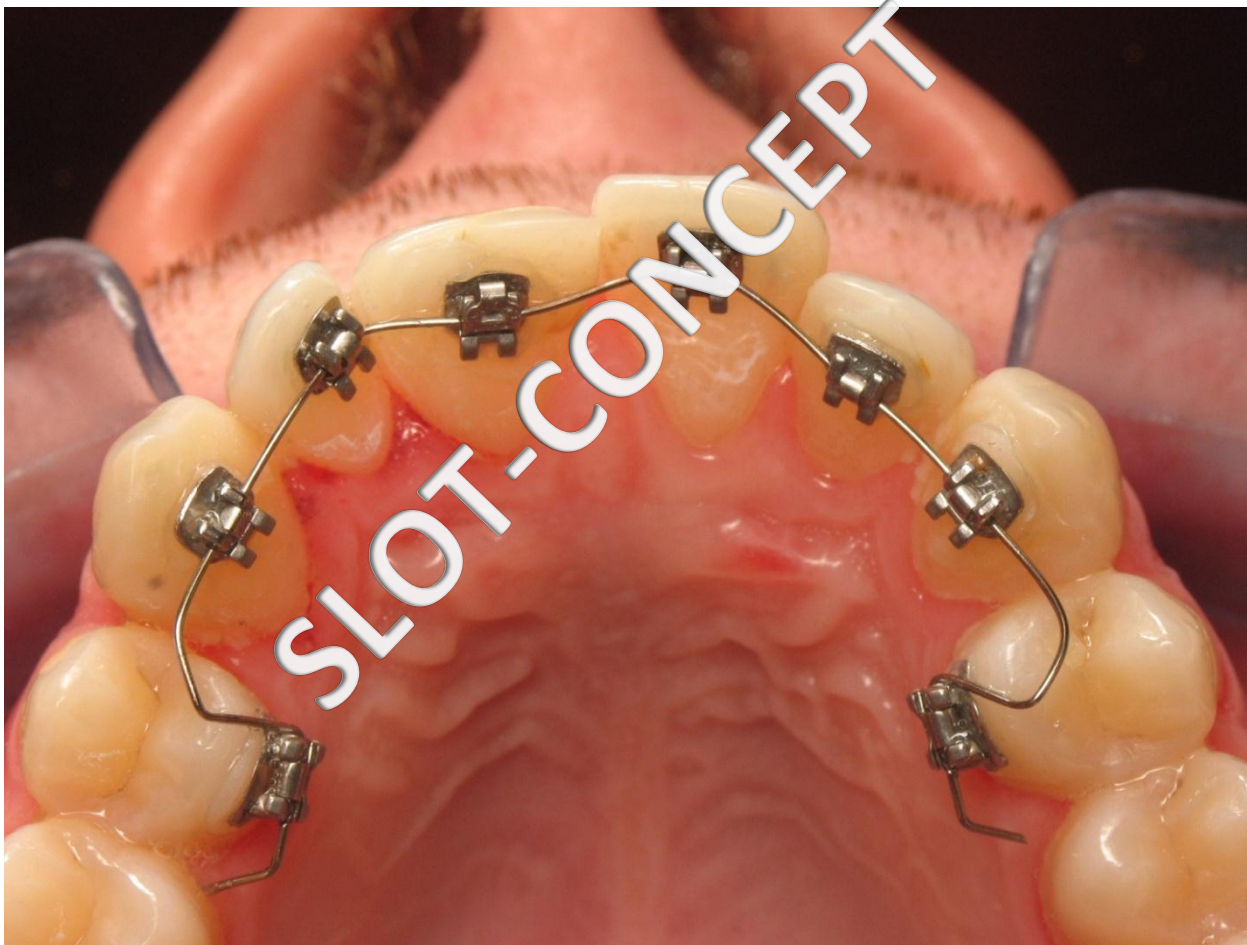


.012 Niti in tension on the inset of form mushroom wire

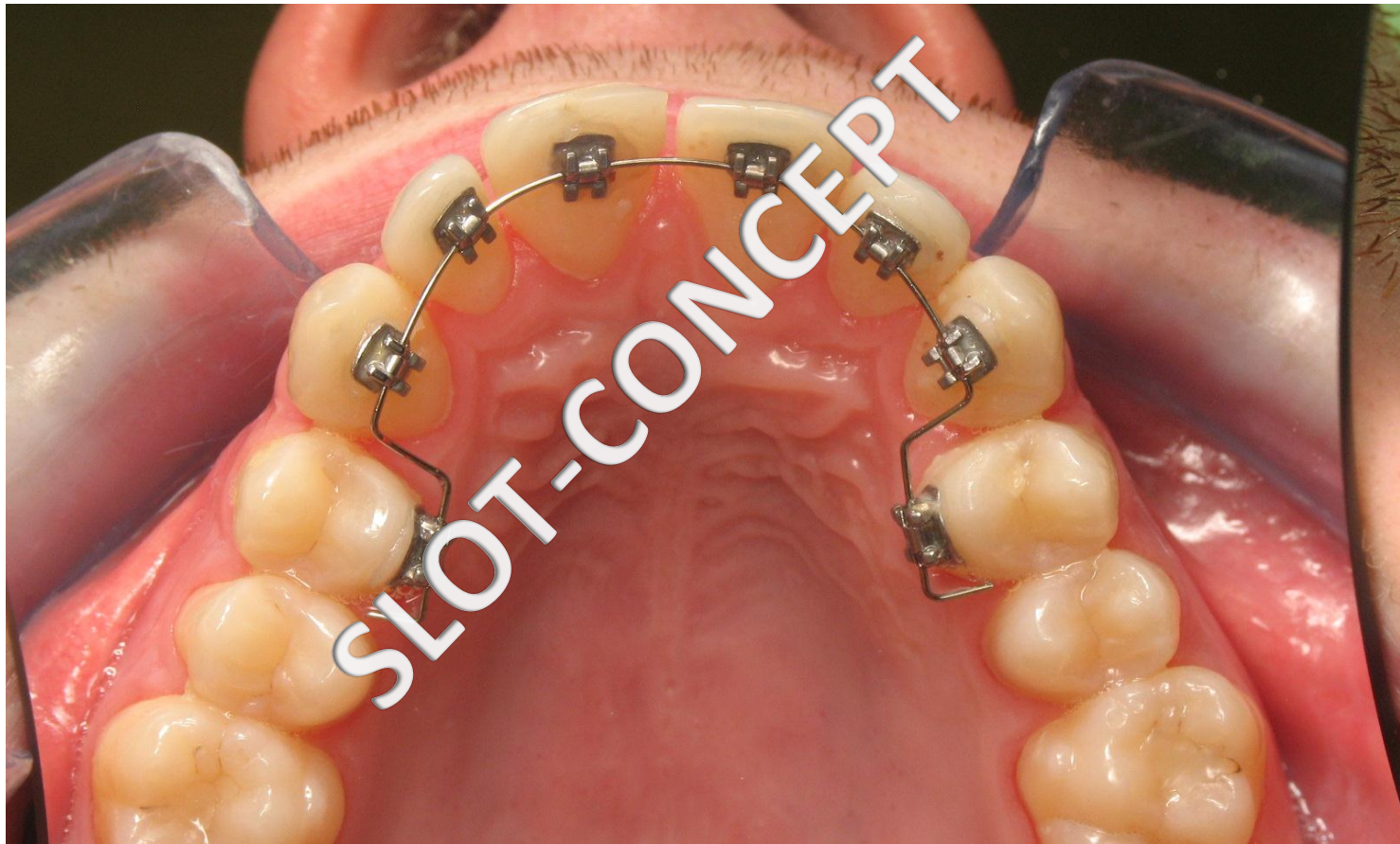2<sup>nd</sup> appointment :4 weeks

Bonding ULR and UCL

.014 Niti in tension (compressive action)

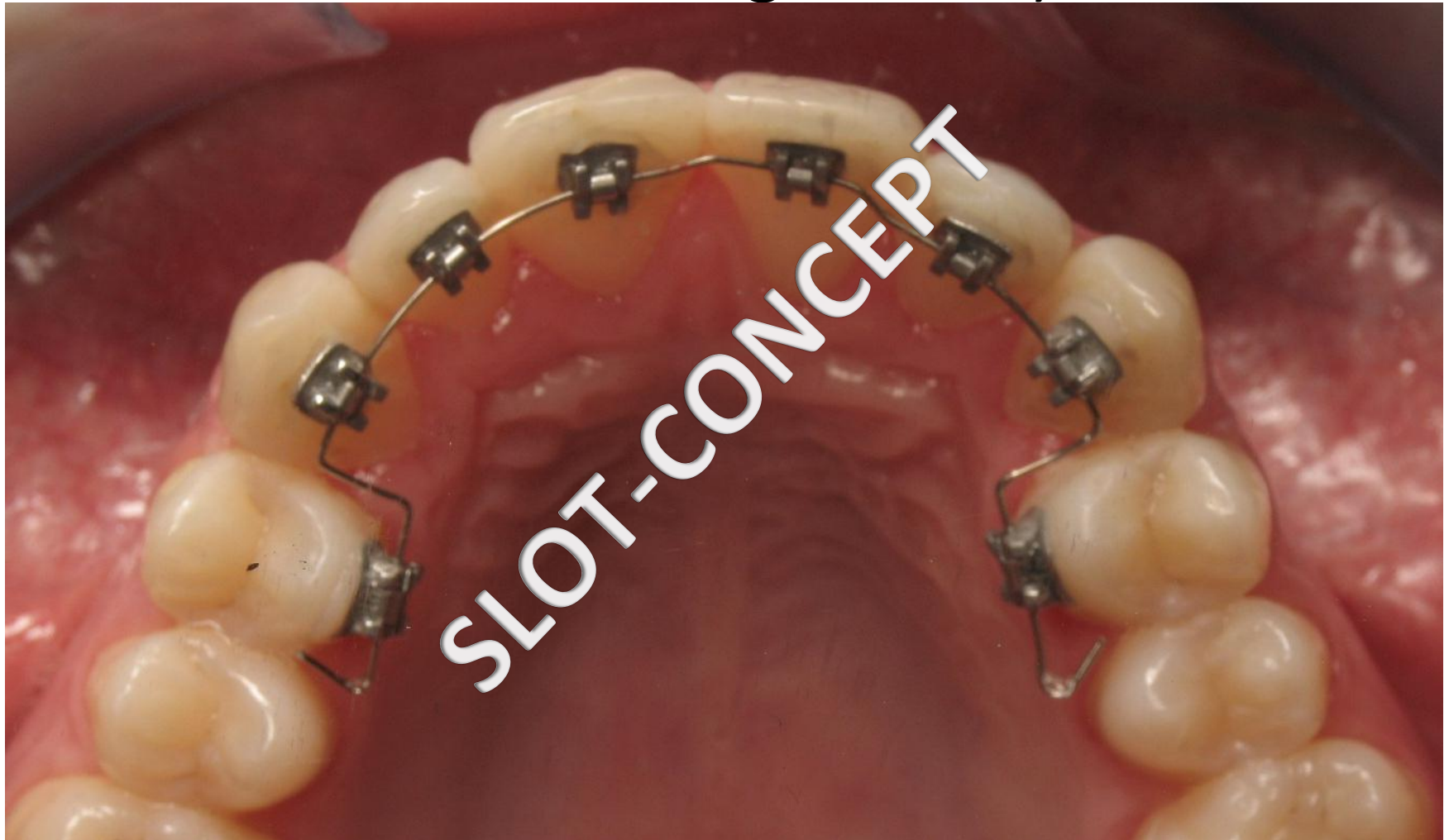

3rd Appointment **8 weeks**  
we achieve leveling

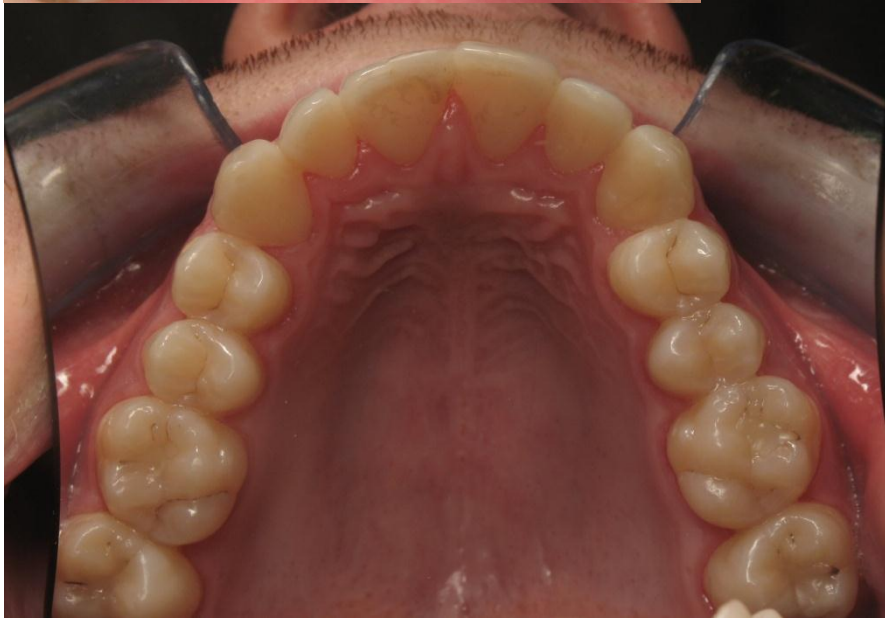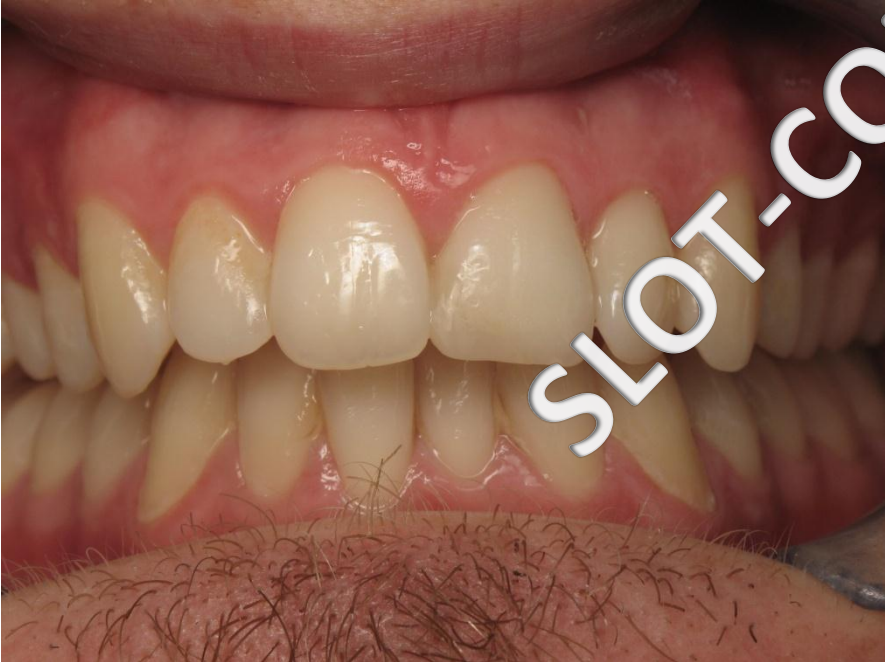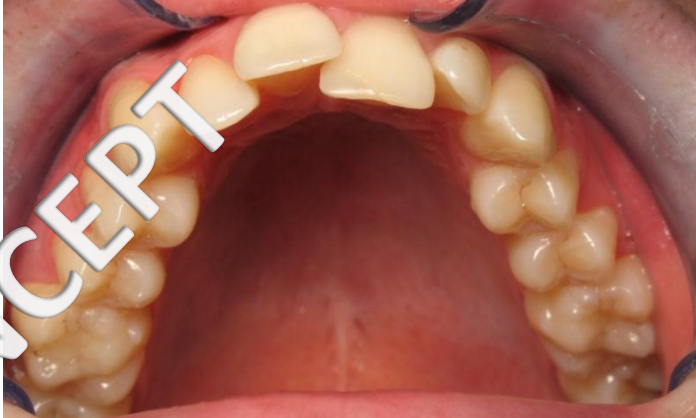


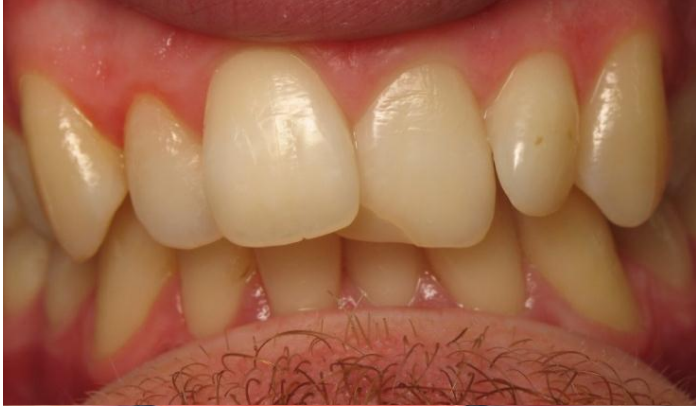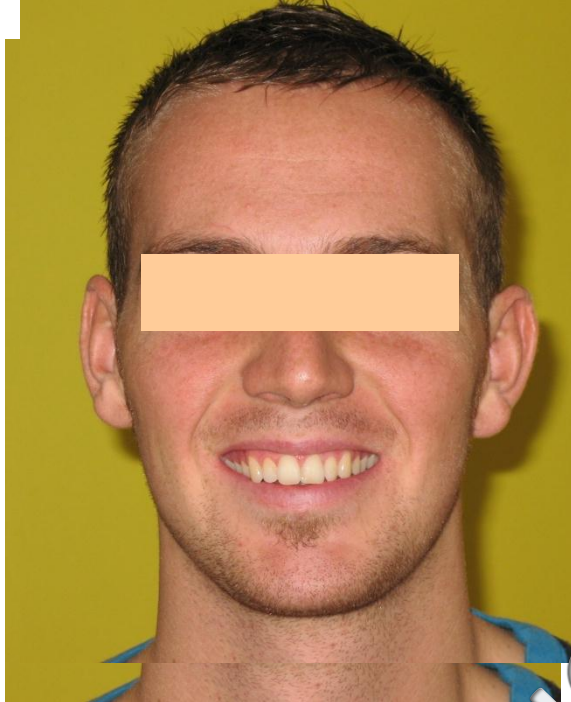4th Month

016 TMA finition (aesthetic deformation  
or bonding finition)



Treatment results  
only 5 months !



SLOT-CONCEPT