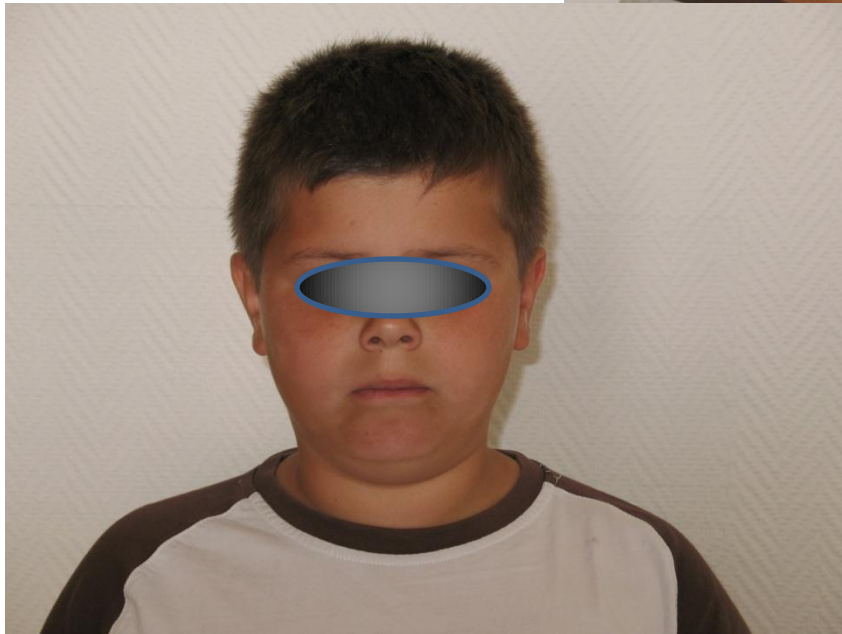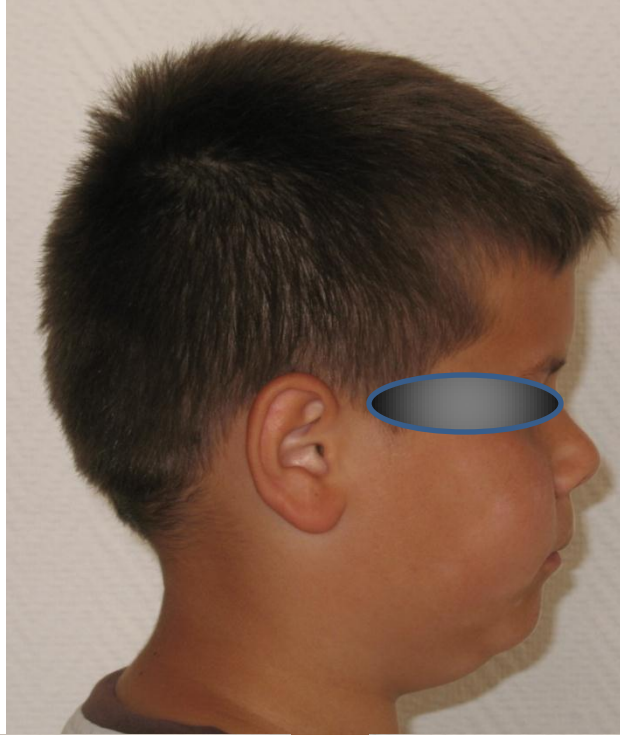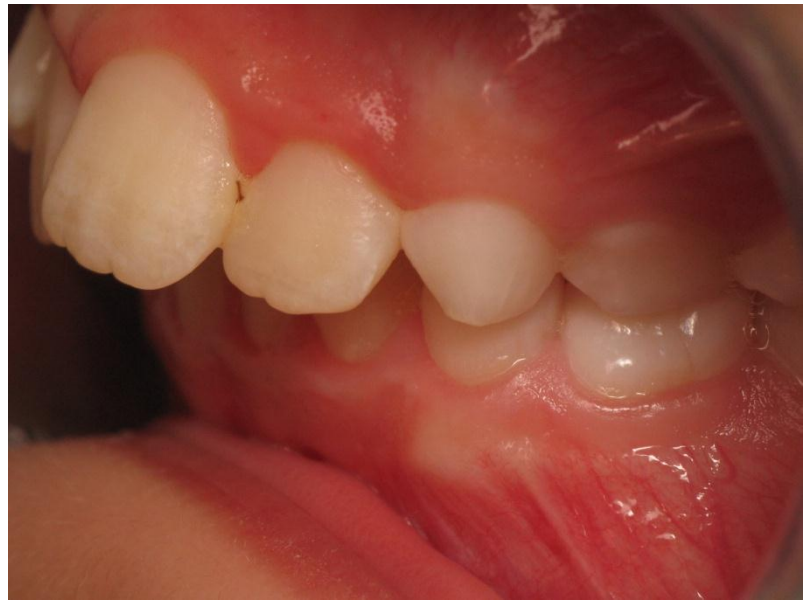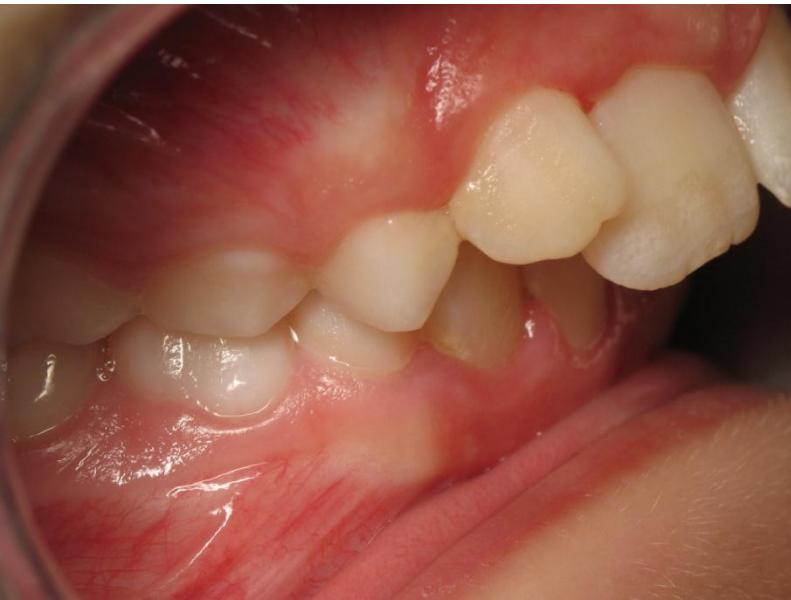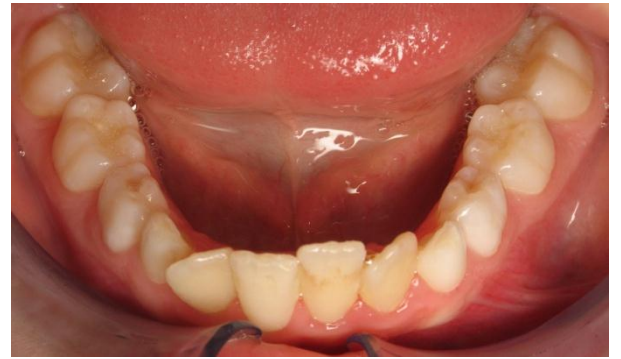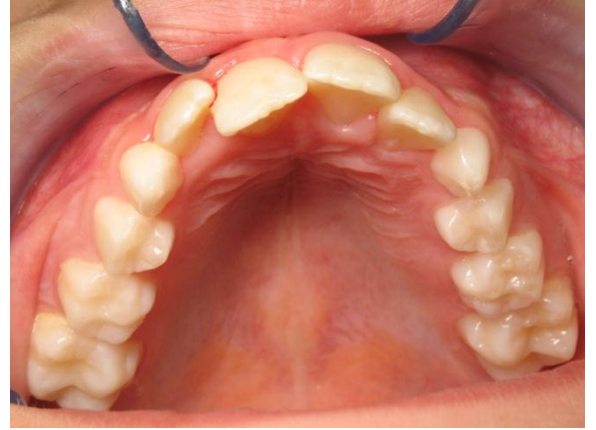


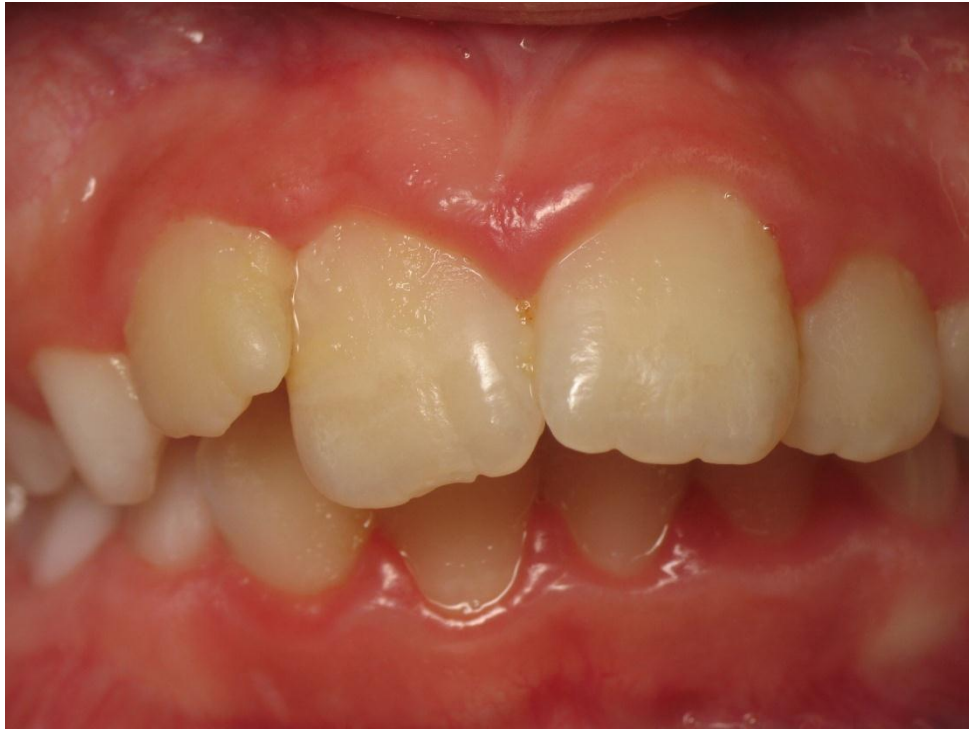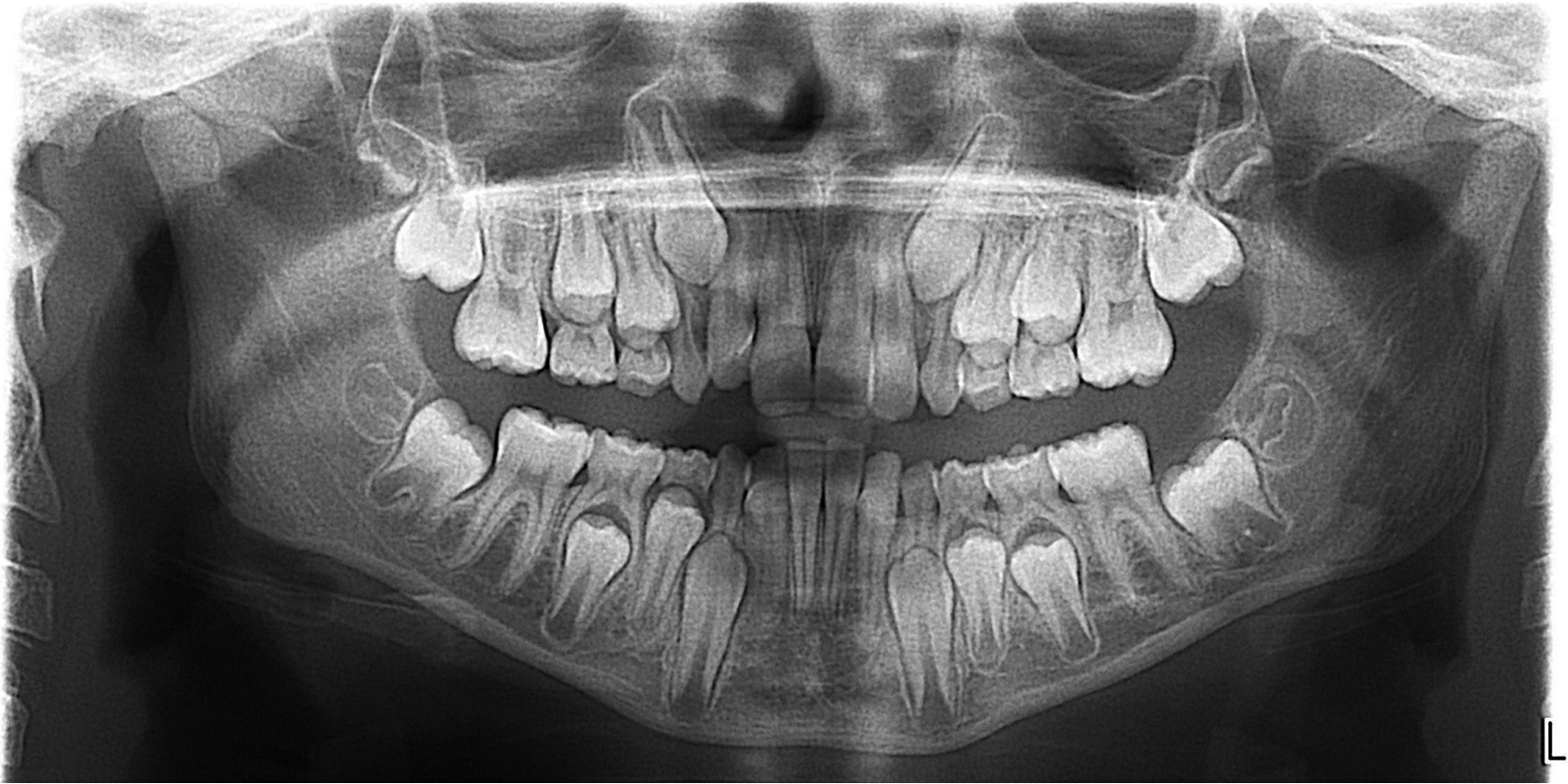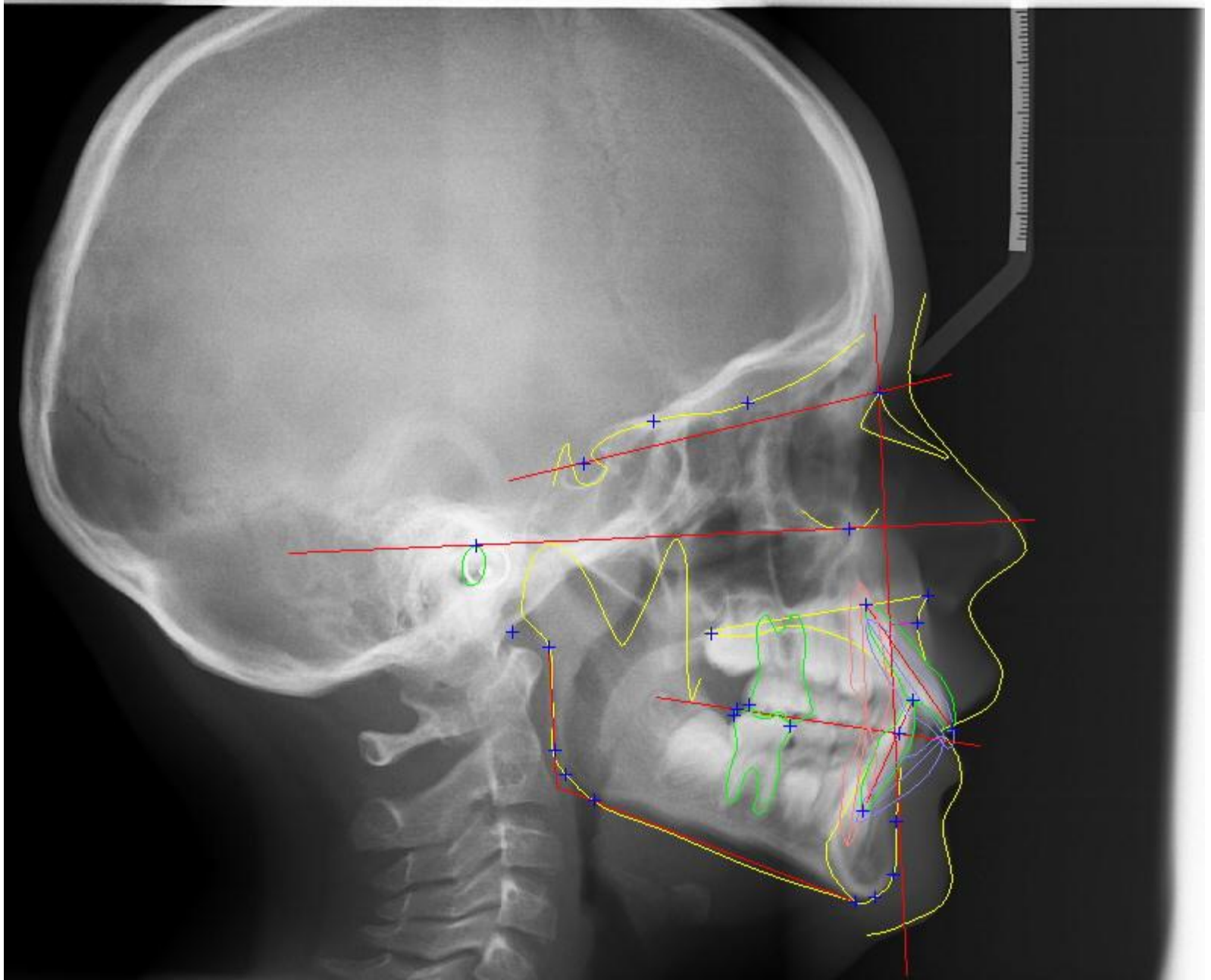
12640



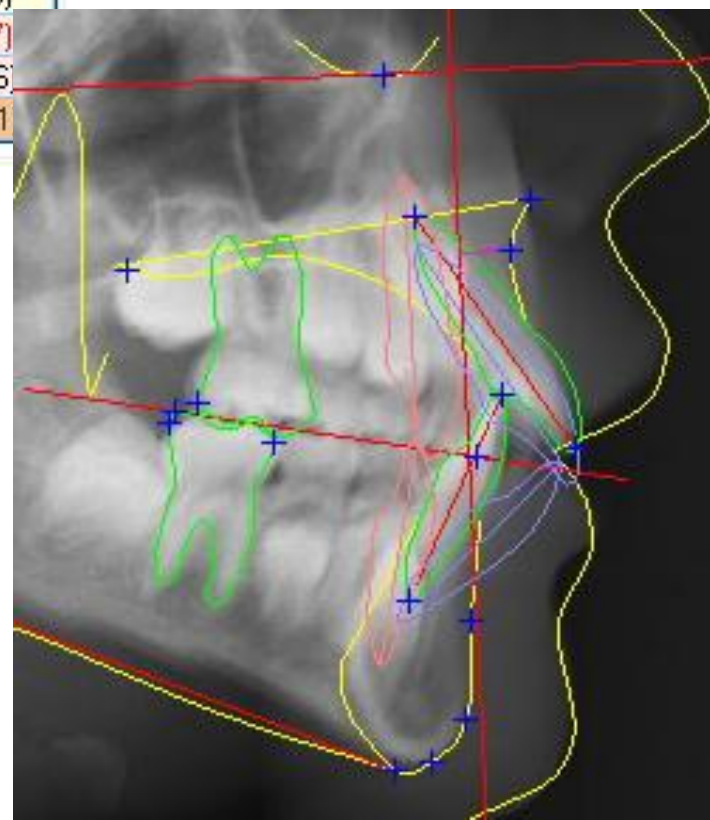
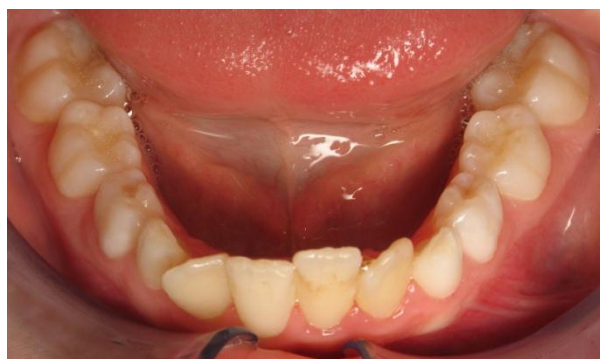






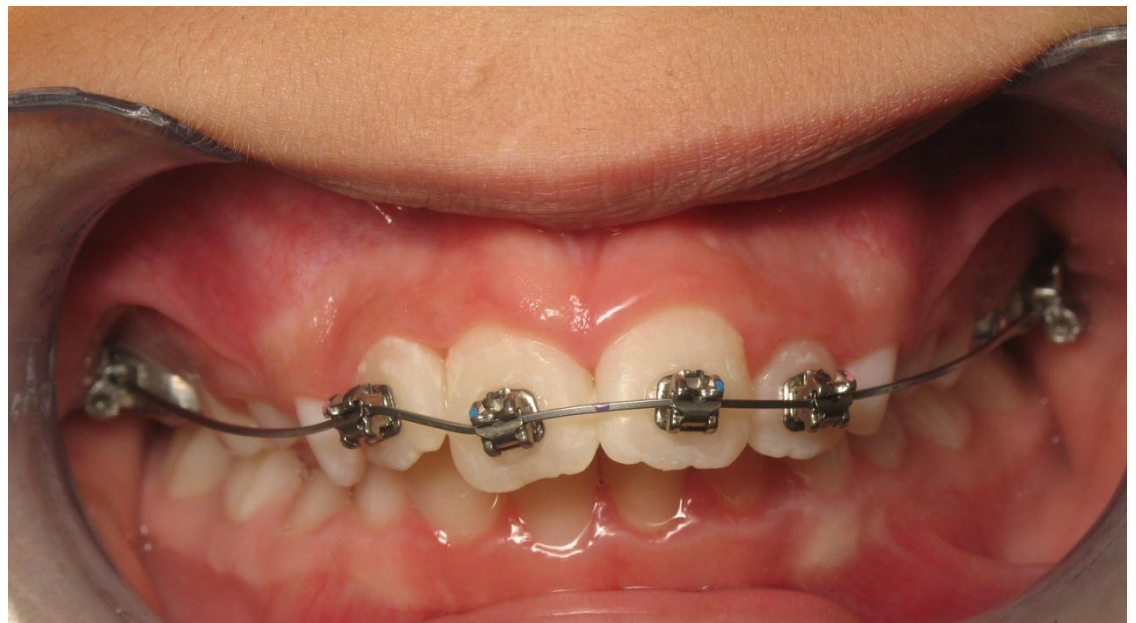
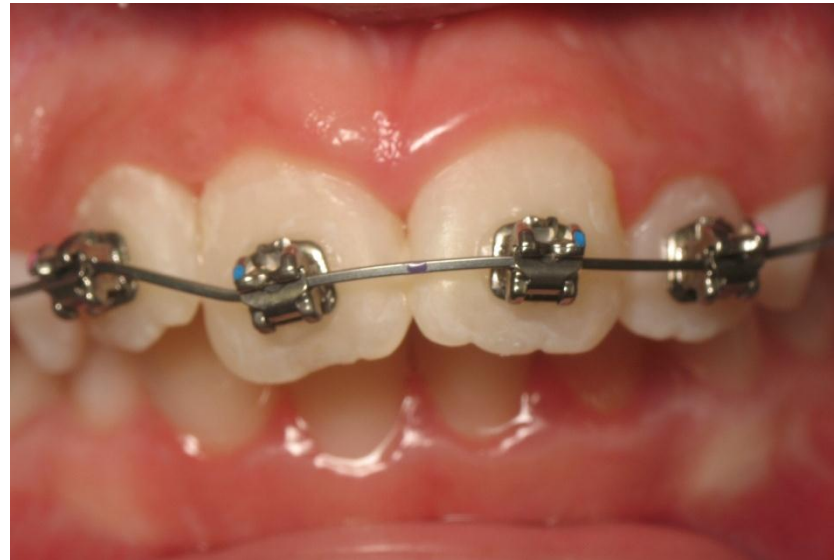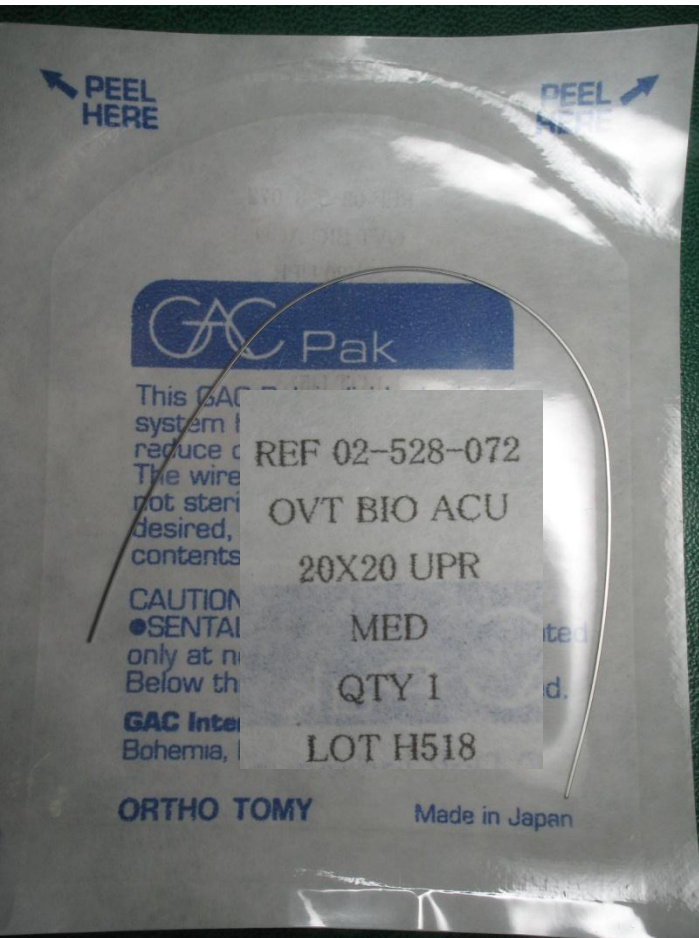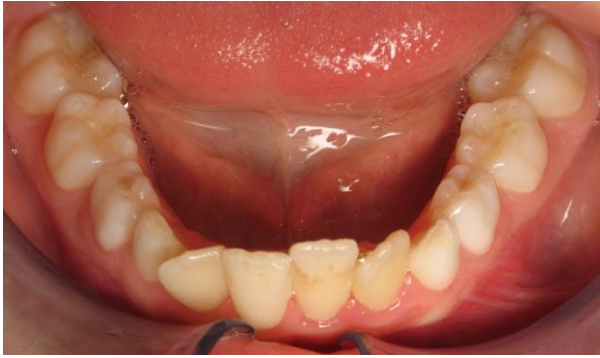Mesure	Evolution	Norme	9 ans 8	
Analyse dentaire		Analyse dentaire		
Surplomb	0.00mm/an +/-0.70	2.60mm	9.91mm	(7.31)
Entrec. Incisif vert.	0.00mm/an +/-1.30	2.30mm	7.05mm	(4.75)
i / Mandibule	0.00°/an +/-9.00	96.00°	93.04°	(-2.96)
I / FH	0.00°/an +/-7.45	112.40°	121.98°	(9.58)
I/Palatin	0.33°/an +/-20.18	106.22°	105.94°	(-0.28)
Inter-incisif	0.00°/an +/-11.63	135.75°	120.98°	(-14.77)
Bord Libre Inc Sup to Stom	-0.08mm/an +/-0.50	2.94mm	-0.13mm	(-3.07)
Analyse osseuse verticale		- Analyse osseuse verticale -		
SN-Plan Mandibulaire	-0.33°/an +/-5.60	30.88°	35.08°	(4.20)
Angle Mandibulaire	-0.83°/an +/-5.70	127.14°	114.56°	(-12.58)
Analyse osseuse antéro-postérieure		- Analyse osseuse antéro-postérieure -		
Déc base A'B'	-0.32mm/an +/-3.15	3.99mm	6.89mm	(2.90)
Point A à Na [L FH]	-0.08mm/an +/-3.15	2.74mm	6.01mm	(3.27)
Point B à Na [L FH]	0.25mm/an +/-4.70	-1.33mm	-0.88mm	(0.46)
Profondeur de la face	1.50mm/an +/-5.00	62.30mm	67.81mm	(5.51)



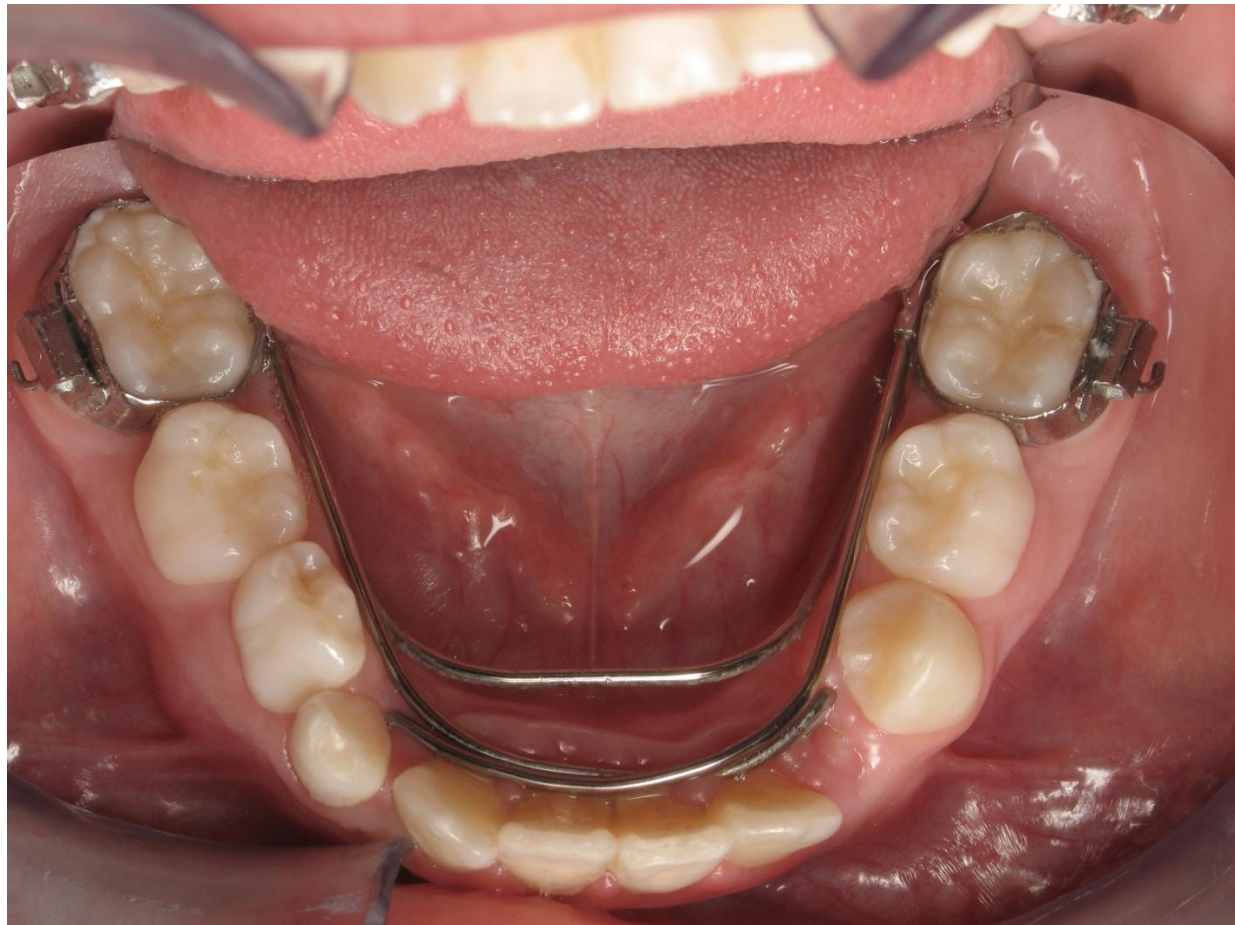


# 1 er arc BIO ACU SUP 20X20 pendant 10 semaine





Deuxième séance: crozat



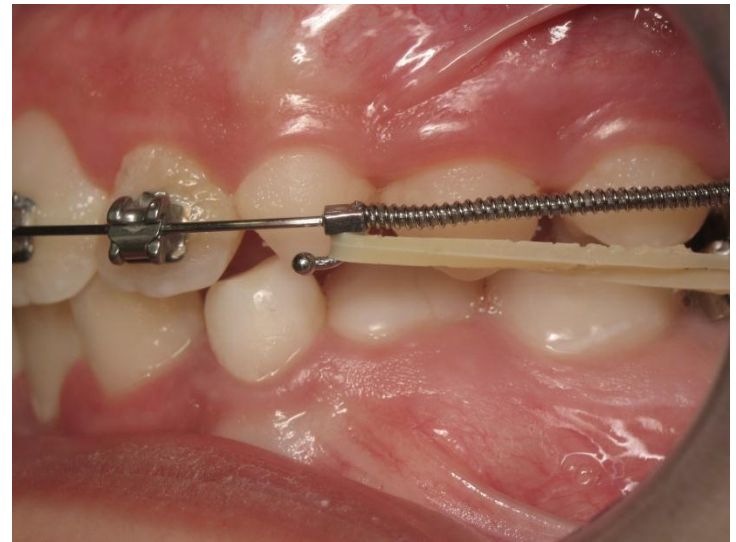
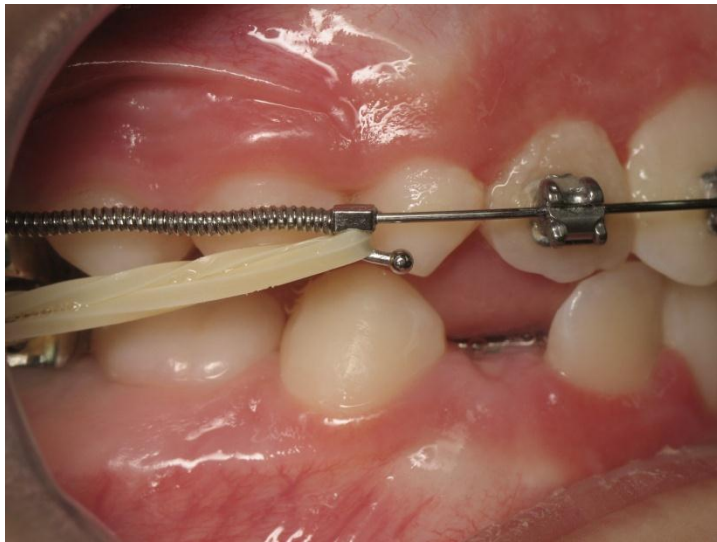
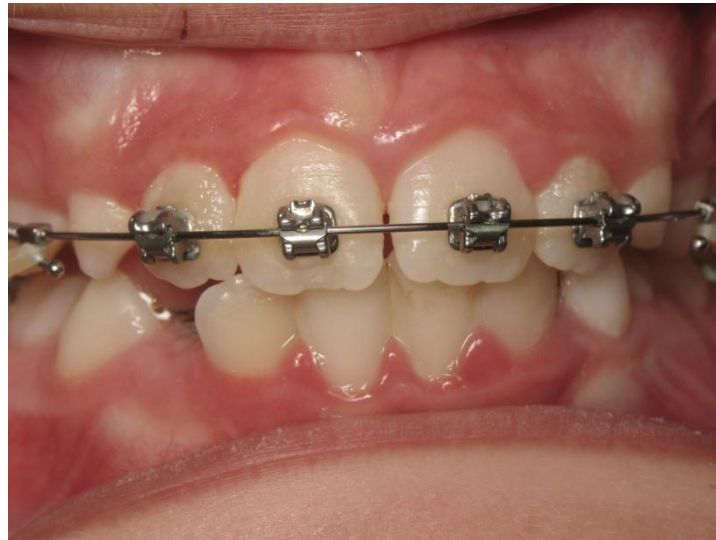

Troisième séance : mise en place d'un 20X25 acier large pendant 4 mois

La CLII est résorbée !

Le contrôle du torque incisif est parfait !

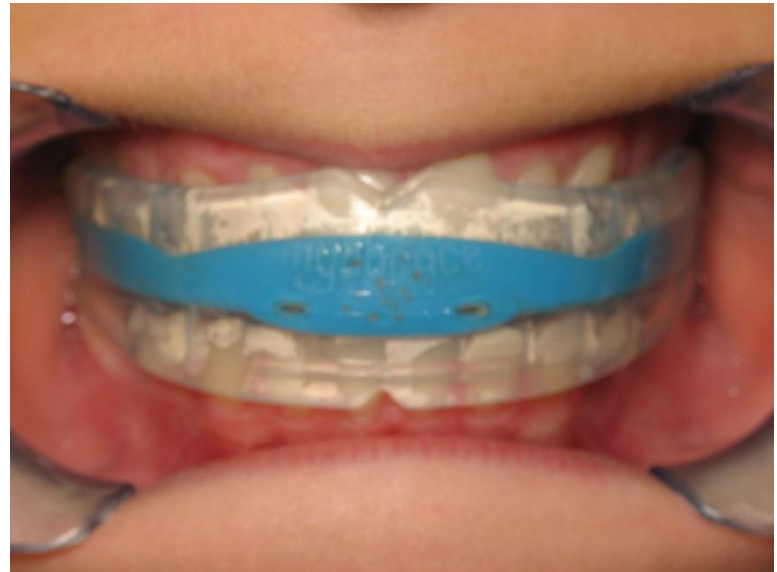Simplicité efficacité confort moindre coût .....

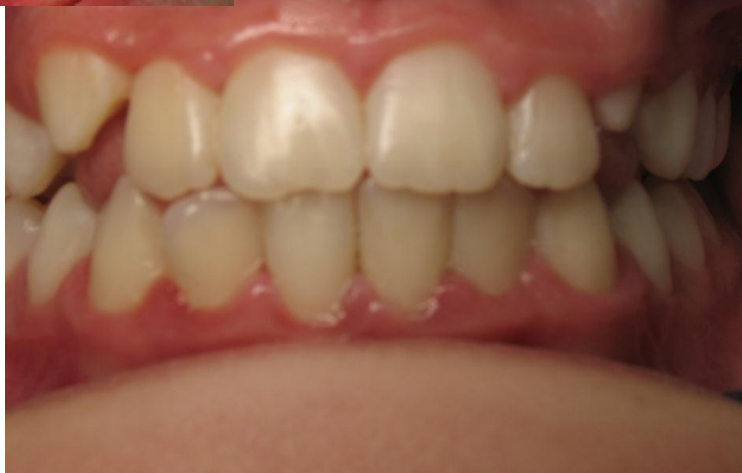
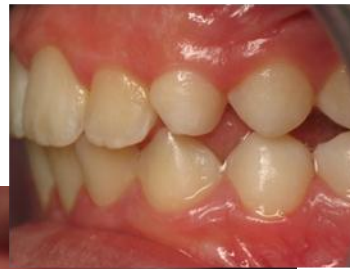
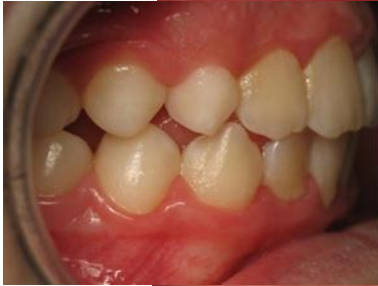
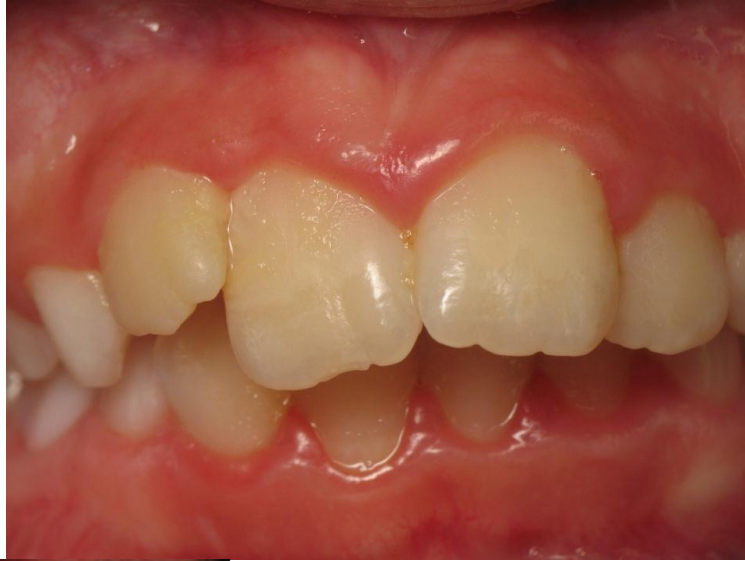
Dépose  
et  
Mise en place d'un myo-trainer MB  
Pour la réhabilitation de la forme d'arcade

Durée 8 mois !

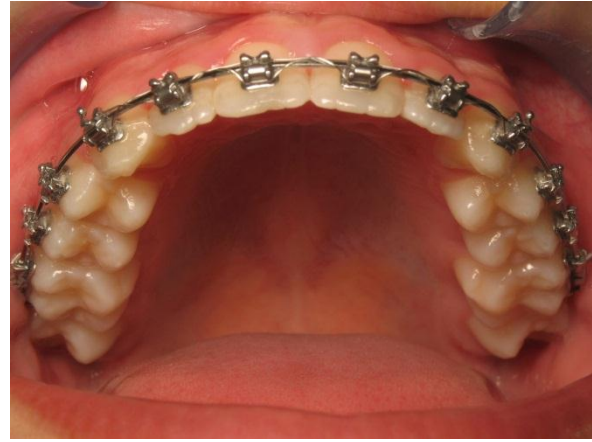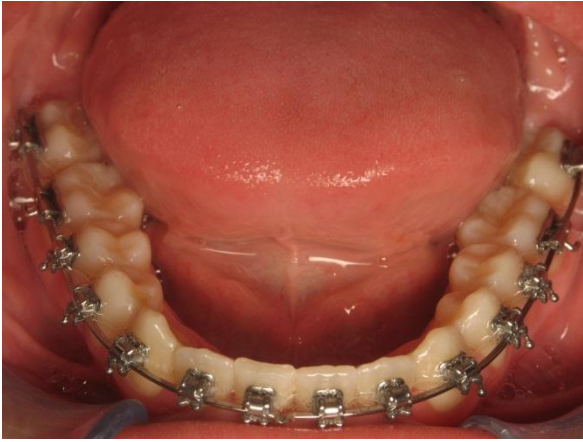




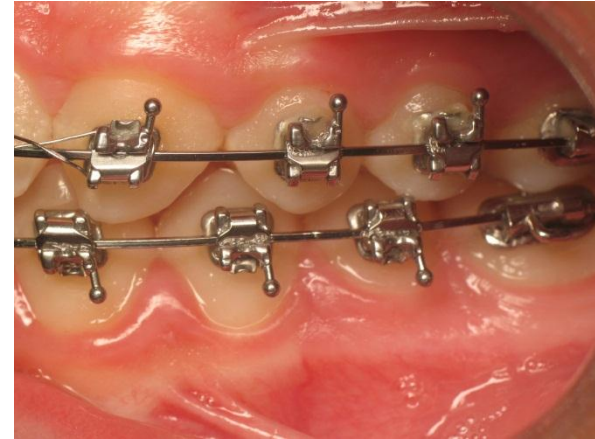
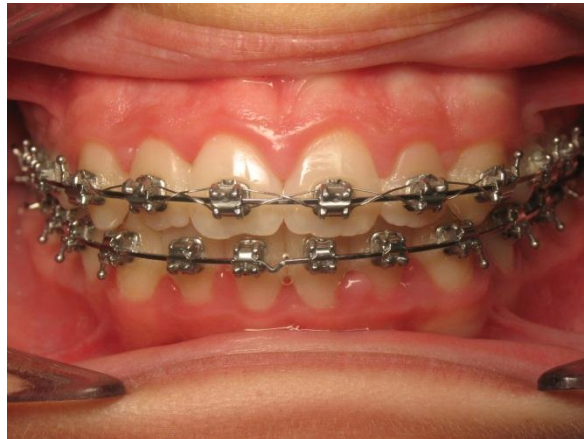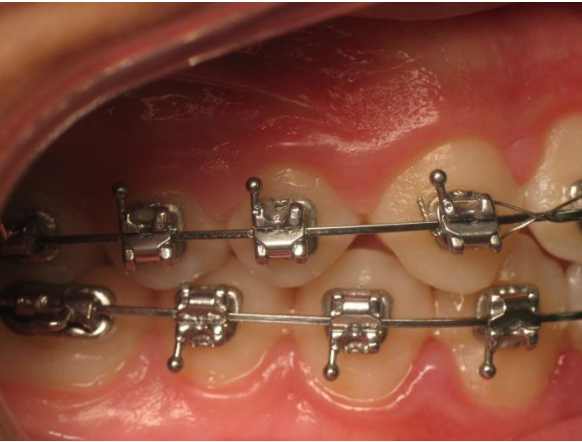
En attendant l'évolution complète en denture définitive

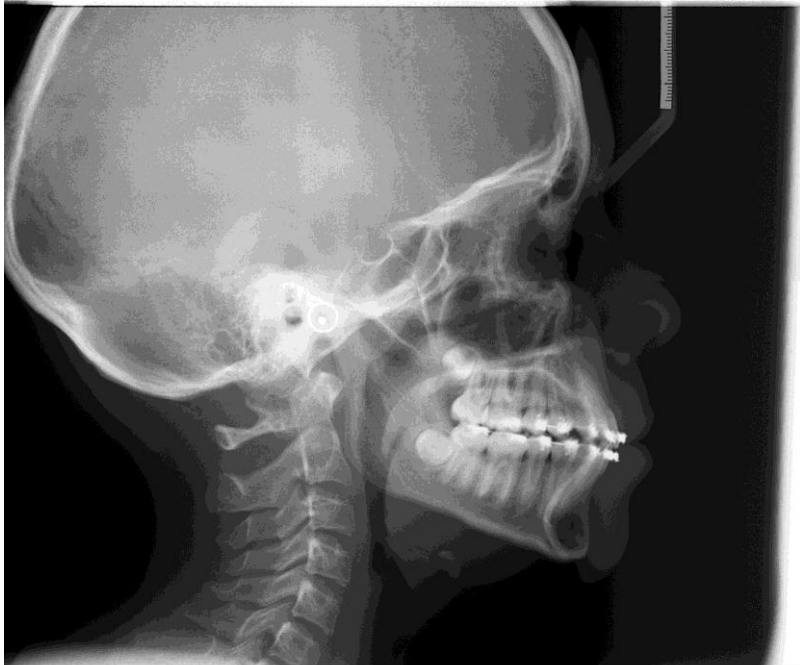




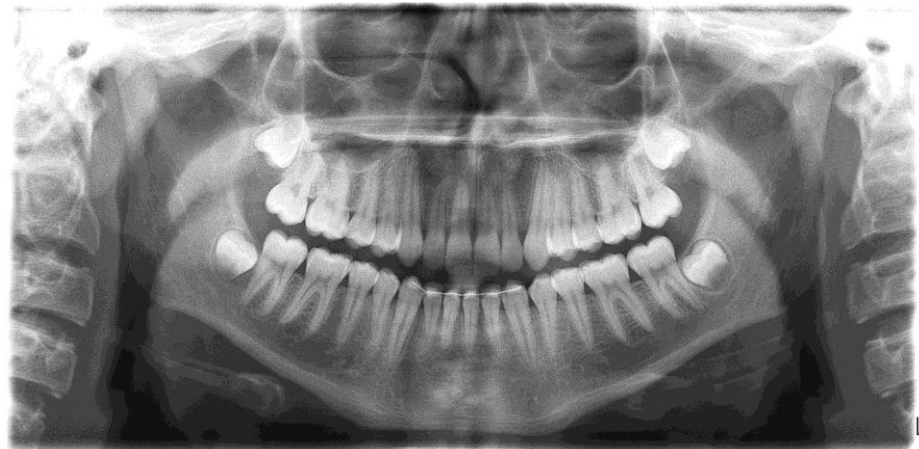


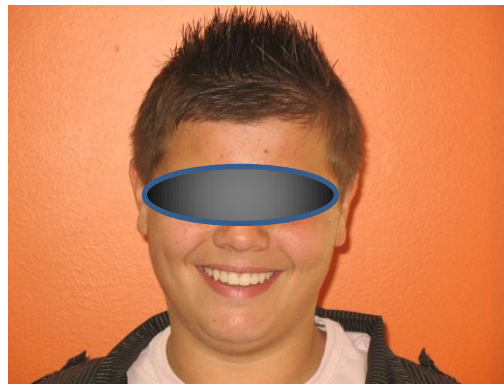
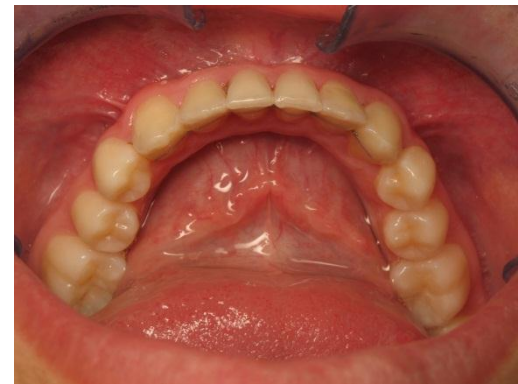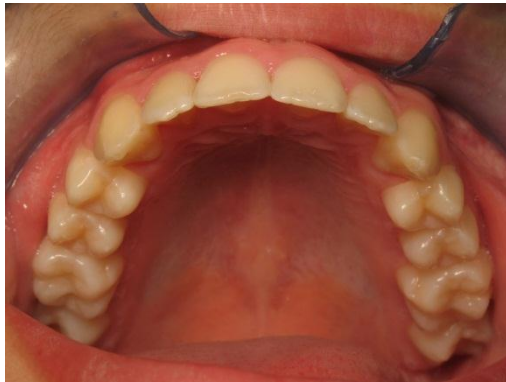Finition en denture définitive





8674 GONDET ALEXIS 08/11/1998  
30/07/2011 70kV 7mA 23.0s 51.8mGy\*cm2 (RD3436171)  
ERNOULT Jean-François  
Docteur Ernoul





Récompense

